

SYSTEMATIC ORAL EXAMINATION

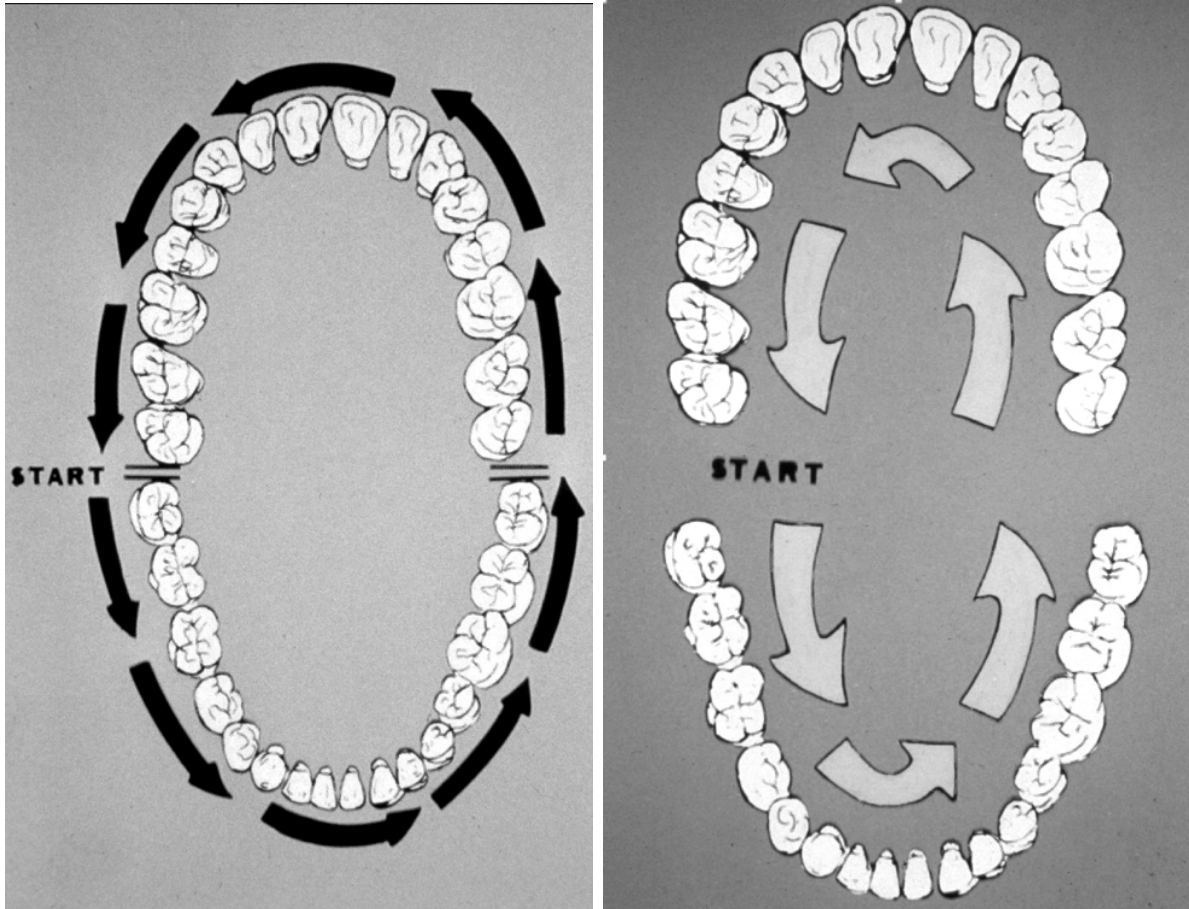
It is estimated that in 2023 there will be 54,540 cases of oropharyngeal cancer. When considering these neoplasms, it is important to separate the oral cavity proper from the pharynx. The oral cavity includes the lips, gingiva, retromolar trigone, hard palate, buccal mucosa, mobile tongue and floor of mouth, whereas the pharynx encompasses the palatine tonsils, soft palate, base of tongue, and lateral and posterior pharyngeal walls.

Although the cause for these cancers appears multifactorial, it is widely known that these neoplasms demonstrate a strong association with tobacco smoking, often combined with alcohol. During the last few decades, attention has been drawn to another carcinogen, human papillomavirus (HPV). At the current time, the prevalence of conventional smoking and alcohol related oropharyngeal cancer is decreasing whereas those associated with HPV are increasing significantly.

Secondary to anatomic reasons, the vast majority of HPV-related cancers DO NOT occur in the oral cavity proper and are thought to arise in mucosa associated with lymphoid tissue. In these areas, the surface mucosa demonstrates deep surface invaginations lined by a unique porous epithelium that is the site of origin for most oropharyngeal HPV-related carcinomas. Approximately 16,000 HPV-related cancers are seen annually in the US and these tumors represent approximately 70% of all oropharyngeal squamous cell carcinomas.

For generations, oral pathologists have taught health practitioners that squamous cell carcinomas present in one of four patterns: leukoplakia, erythroplakia, chronic ulceration or zones of mucosal granularity. Due to origin within deep surface invaginations, HPV-related cancer often presents as a submucosal mass that cannot be visualized and is discovered best by palpation.

The systematic oral examination described today must be done twice. The first pass concentrates on visually obvious mucosal alterations while the second pass utilizes palpation to discover subtle submucosal masses. While performing these examinations, the oral mucosa is divided into the tissue lateral to the teeth, medial to the teeth and the tongue. Each segment must be examined systematically and thoroughly with the following images utilized as a guide.



A number of oral diagnostic adjuncts currently are being marketed and may be discussed. The 2017 ADA position paper said it best: *"No available adjunct demonstrated sufficient diagnostic test accuracy to support their routine use as triage tools during the evaluation of lesions in the oral cavity."* Conventional oral examination remains the standard of care for the discovery of significant oral pathoses.